

Early Selective Angioembolization Improves Success of Nonoperative Management of Blunt Splenic Injury

SHIH-CHI WU, M.D.,* KUAN-CHIH CHOW, Ph.D.,† KUN-HUA LEE, M.D.,* CHENG-CHENG TUNG, M.D.,*
ALBERT D. YANG, M.D.,‡ CHONG-JEH LO, M.D., F.A.C.S.§

From the *Division of Trauma and ‡Department of Radiology, Changhua Christian Hospital, Changhua, Taiwan; †Graduate Institute of Biomedical Sciences, National Chung Hsing University, Taichung, Taiwan; and §Department of Surgery, National Cheng-Kung University, College of Medicine, Tainan, Taiwan

The role of angioembolization in the management of patients with blunt spleen injury is still under debate. Our study examined the impact of splenic artery embolization (SAE) on the outcome of such patients. We reviewed 114 consecutive blunt abdominal trauma patients with isolated splenic injury over a period of 40 months, including 61 patients seen before (Group A) and 53 patients seen after (Group B) the adoption of SAE. Hemodynamically unstable patients underwent the abdominal exploration and stable patients were evaluated with CT scans of abdomen and pelvis. Patients underwent SAE based on the findings of CT scans, including contrast extravasation or large hemoperitoneum. For initially stable patients, there were no differences in nonoperative management success rate between Groups A and B in regards to injury severity score ≥ 16 , age, or grades of splenic injury ≥ 3 . In comparison, among patients with large hemoperitoneum found by abdominal CT, Group B had significantly better nonoperative management success rates ($P < 0.05$). SAE was successful to control bleeding in 80 per cent of patients. Partial splenic infarction was noted in all patients after the procedure but it resolved by six months. By using criteria developed based on abdominal CT scans for angioembolization, we are able to improve nonoperative splenic salvage rate.

NONOPERATIVE MANAGEMENT (NOM) of blunt splenic injury (BSI) in hemodynamically stable patients is widely accepted.¹⁻³ Operative procedures are only reserved for patients with hemorrhagic shock or with additional intra-abdominal injury requiring exploration. Although these stable patients would undergo the abdominal CT to delineate the splenic injury, it remains unclear whether certain radiographic findings on CT, such as contrast blush, large amount of hemoperitoneum, or high grade of splenic injury would benefit from additional management including splenic artery embolization (SAE). Sciafani et al.⁴ used selective splenic artery embolization for patients with contrast extravasation and found a higher success rate of nonoperative management of BSI. Similarly, Haan et al.⁵ demonstrated a better splenic salvage rate with SAE in higher grades of splenic injury with to-

mographic evidence of active bleeding. In contrast, Omert et al.⁶ showed that contrast blush on CT scan merely related to higher grades of splenic injury and therefore it was not, by itself, an absolute indication for an operative procedure. SAE is an effective alternative or adjunct for hemostasis after splenic injury and may play an important role in the nonoperative management of splenic injury.^{5, 7, 8} Intuitively, SAE should be performed as soon as contrast extravasation is discovered and before the deterioration of hemodynamics occurs. However, it remains controversial whether the patient who has the splenic injury, delineated by CT scanning, but becomes hemodynamically unstable could undergo SAE.^{9, 10} In addition, because contrast blush is frequently detected during a repeated CT scanning,¹⁰ the role of routine follow-up radiographic evaluations deserves further investigation even in a stable patient with no clinical indications.

In this study, we investigated whether SAE was effective and safe in the management of BSI and how this intervention would affect the outcome. We also discussed factors that influence the success rates of NOM.

Address correspondence and reprint requests to Chong-Jeh Lo, M.D., F.A.C.S., Associate Professor, Department of Surgery, National Cheng-Kung University, College of Medicine, 138 Sheng-Li Road, Tainan, Taiwan. E-mail: jehlo@mail.ncku.edu.tw.

Patients and Methods

We retrospectively reviewed blunt splenic injury patients admitted to Changhua Christian Hospital (CCH) from July 2001 to October 2004. CCH serves as the primary health institution for a district of 1.31 million residents. In addition, CCH operates as a major trauma referral center for hospitals in Changhua and surrounding counties. Critically injured patients are either transported directly to CCH by the emergency medical service or are transferred from local community hospitals after the initial management. On presentation to the emergency room, all patients are treated by one of four staff trauma surgeons and a trauma resuscitation team. Full-time consultants are either in-house or are readily available for consultation in all specialties.

Patients with hemorrhagic shock and persistent hypotension unresponsive to fluid resuscitation or with obvious peritonitis are taken directly to the operating room after ultrasound examination of the abdomen and a chest X-ray. Surgical procedures include splenectomy or splenorrhaphy. Patients with initially stable hemodynamics, or rapidly normalized hemodynamics after resuscitation are evaluated with CT scans of the abdomen and pelvis. Scans are obtained using a GE Light Speed Scanner (GE Medical Systems, Milwaukee, WI). Patients receive 100 mL of intravenous bolus of nonionic contrast Ioversol (Optiray®, Mallinckrodt Inc., Hazelwood, MO). Ten-millimeter cuts are obtained from the lower chest through the pelvis.

All CT scans are initially read by staff trauma surgeons and are later reviewed by staff radiologists. Contrast extravasation/contrast blush is defined as a focus of high-attenuation contrast material located either in the splenic parenchyma or outside the capsule. Large hemoperitoneum indicates blood accumulation in both upper quadrants and pelvis.² Splenic injuries are classified according to the grading scale defined by the American Association for the Surgery of Trauma.¹¹ A hilar injury is defined as an injury at the junction of the spleen artery and vein seen during operation or read by an experienced radiologist on CT scans. Patients who remain hemodynamically stable after CT examination and without signs of peritonitis are admitted to the surgical intensive care unit or the ward. Mandatory celiotomy is performed in patients whose vital signs deteriorate or who require continuous blood transfusion or fluid resuscitation. We define NOM failure as patients who undergo celiotomy after being admitted to the intensive care unit or ward.

Since July of 2003, we have adopted angiography and embolization in the management of blunt splenic injuries. Figure 1 shows the algorithm of the treatment plan. The criteria for angioembolization include 1) stable hemodynamics or those rapidly normalized after resuscitation, 2) abdominal CT revealing contrast extravasation or splenic injury with large hemoperitoneum, and 3) no other obvious signs or symptoms of hollow organ perforation that mandate celiotomy. The arterial access is obtained via right femoral artery. A

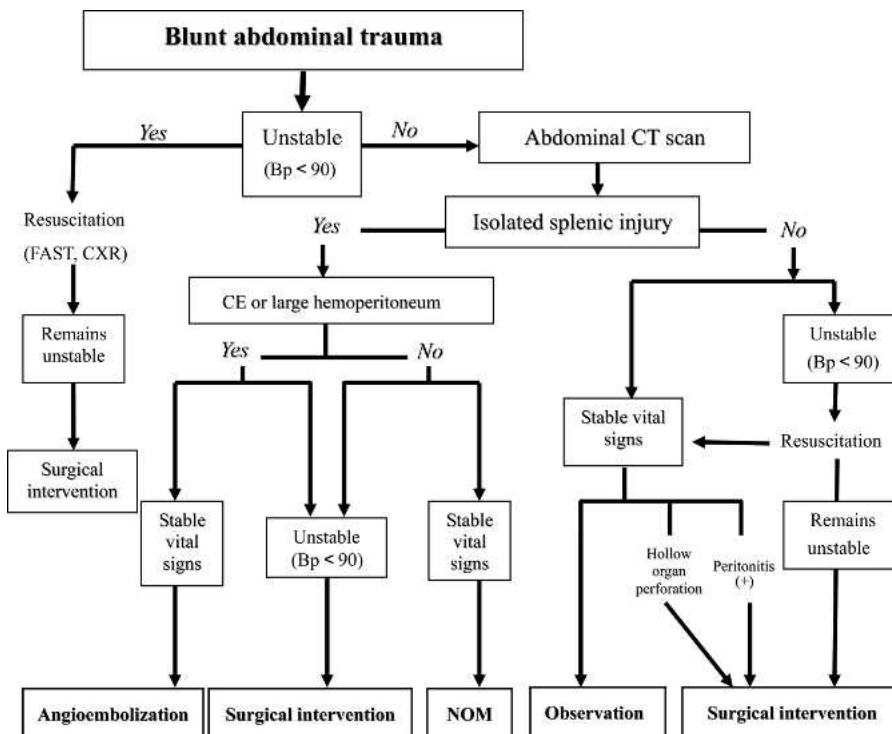


FIG. 1. Algorithm for treatment of patients with blunt splenic trauma.

TABLE 1. Demographic Characters of Patients with Blunt Splenic Injury

	Group A (n = 61)	Group B (n = 53)	P Value
Male/female	43/18	38/15	0.887
Age	38.8 ± 19.3*	36.8 ± 19.1*	0.574
ISS	19.9 ± 11.2*	20.3 ± 10.3*	0.842
Age >55	24.5%	24.5%	0.994
Injury mechanism (MCC)†	54.0%	71.6%	0.294
Spleen injury grade ≥ III‡	86.8%	83.0%	0.563
Splenic hilar injury	19.7%	32.1%	0.129
Large hemoperitoneum§	31.1%	39.6%	0.343
NOM success rate	55.7%	54.7%	0.913
ICU stay (days)†	2.2 ± 3.8*	4.8 ± 9.9*	0.075
Ward stay (days)	9.2 ± 5.9*	7.4 ± 5.7*	0.108

* Values are mean ± standard deviation, P value was determined by χ^2 test or Mann-Whitney U test.

† MCC, motorcycle crash; ICU, intensive care unit.

‡ Splenic injury grade according to American Association for the Surgery of Trauma Organ Injury Scale.

§ Free blood seen in both upper quadrants and pelvis on CT scans.

#5 French RC1 catheter (Cook Inc., Bloomington, IN) is then advanced into the splenic artery. Gelfoam® (Pharmacia & Upjohn, Somerset County, NJ) is used as the embolizing agent that is injected during the angiography. Intrasplenic vessels are embolized whenever possible and the main splenic artery is embolized when needed for bleeding control. Celiotomy is promptly performed in patients who experience episodes of hypotension in the intensive care unit after angioembolization.

We compared patients who were either admitted before (Group A) and after (Group B) the adoption of angioembolization for splenic injuries. Data extracted for analysis included demographics, mechanism of injury, injury severity score (ISS), the time interval to operation, abdominal CT findings, operative findings, first 24-hour blood transfusion, and final outcome. There were no discrepancies in patient care or the surgical facility between the two phases of the study period. Patients with additional intra-abdominal organ injury were excluded from this study.

Data were then entered into a desktop computer and

analyzed using the SPSS 10 software (SPSS Inc, Chicago, IL). Statistical significance (P value < 0.05) was determined using χ^2 (or Fisher's exact, when $n \leq 5$) or Mann-Whitney U tests.

Results

There were 139 patients who were diagnosed to have blunt splenic injuries. Of those, 25 were excluded due to multiple intra-abdominal organ injuries. Therefore, only 114 patients were in our study, including 61 patients in Group A and 53 patients in Group B. Average age of patients were 38.8 ± 19.3 (ranging from 3 to 74) years for patients in Group A and 36.8 ± 19.1 (ranging from 3 to 71) years for Group B. There were no significant differences in all demographic characters examined between Groups A and B (Table 1). Motorcycle crash was the most common mechanism of injury and accounted for 54 per cent and 72 per cent of blunt abdominal trauma in Group A and Group B, respectively.

Table 2 showed the treatment outcome of patients

TABLE 2. Patient Management Before (Group A) and After (Group B) the Adoption of Splenic Arterial Embolization (SAE)

Treatment	Group A (n = 61)		Group B (n = 53)	
Directly to OR*	9	(SN*:4) (SR*:5)	7	(SN:6) (SR:1)
Unstable hemodynamics during CT scans	5	(SN:4) (SR:1)	13	(SN:7) (SR:6)
NOM Success	34		29	
NOM failure	13		4	
Late failure†	3	(SN:2) (SR:1)	2	(SN:2) (SR:0)
Early failure‡	10	(SN:10)	10	(SN:2)§
SAE				

* OR, operating room; SN, splenectomy; SR, splenorrhaphy.

† Patients who failed NOM and went to the OR beyond 24 hours of admission.

‡ Patients were stable hemodynamically after CT scans but became unstable within 2 hours of observation.

§ Patients who failed SAE underwent splenectomy.

TABLE 3. Comparison of Nonoperative Management (NOM) Success Rates in Patients with Splenic Injury Between Groups A and B*

Factors	Group	Success	Failure	P Value†
ISS \geq 16	A (n = 26)	18 (69.2%)	8 (30.8%)	0.485
	B (n = 16)	13 (81.3%)	3 (18.8%)	
Age \geq 55	A (n = 11)	10 (90.1%)	1 (9.1%)	0.099
	B (n = 6)	3 (50.0%)	3 (50.0%)	
Hilar injury‡	A (n = 6)	0 (0.0%)	6 (100.0%)	0.070
	B (n = 7)	4 (57.1%)	3 (42.9%)	
Spleen injury§ (Grade \geq III)	A (n = 39)	26 (66.7%)	13 (33.3%)	0.286
	B (n = 24)	19 (79.2%)	5 (20.8%)	
Large hemoperitoneum¶	A (n = 16)	4 (25.0%)	12 (75.0%)	0.019
	B (n = 7)	6 (85.7%)	1 (14.3%)	

* Excluding unstable patients on presentation or patients becoming unstable during CT scans.

† Significance (*P* value) determined by χ^2 test or Fisher's exact test.

‡ Hilar injury based on the abdominal CT or operative findings.

§ Splenic injury grade according to American Association for the Surgery of Trauma Organ Injury Scale.

¶ Free blood seen in both upper quadrants and pelvis on CT scans.

with blunt splenic injuries. Nine patients in Group A were unstable on presentation and went to the operating room immediately. In addition, five patients became hemodynamically unstable during CT scans and were also taken to the operating room. Forty-seven patients were managed nonoperatively with 10 early failures (<2 hours of admission) and three late failures (>24 hours of admission). Seven patients in Group B were unstable on presentation and 13 patients became unstable during CT scans. All were taken to the operating room. Thirty-three patients were managed nonoperatively, including 10 patients that underwent SAE. Two patients continued to bleed after SAE and underwent splenectomy. The other two were operated more than 24 hours later (late failures).

NOM success rates of stable patients between two groups stratified based on ISS \geq 16, age \geq 55, the presence of hilar injury, the grades of splenic injury \geq 3, and large hemoperitoneum and were shown in Table 3. Among patients with large hemoperitoneum, Group B had significantly better NOM success rates than Group A (*P* = 0.019). Similarly, in patients with hilar injuries on CT scans, there was also a trend toward better NOM success rates in Group B.

Four of the five patients in Group A, who became unstable during CT scans, had contrast extravasation on CT scans (Table 4). The other 10 patients were hemodynamically stable initially after the study, but became unstable within two hours of observation. The images of these patients showed contrast extravasation

TABLE 4. Comparison of Management Between Group A (Before SAE) and Group B (After SAE)

	Unstable Hemodynamics During CT Scans‡		Stable Hemodynamics After CT Scan§	
	A (n = 5)	B (n = 13)	A (n = 10)¶	B (n = 10, SAE)
Splenic salvage rate (%)	1/5 (20%)	6/13 (46.2%)	0/10 (0%)	8/10 (80%)
<i>P</i> value		0.596		0.001
Time to operation (min)	112 \pm 13	120 \pm 54	183 \pm 61	—
<i>P</i> value		0.902		0.002¶
CT findings	†CE:4 †LH:0 †Gr III:1	CE:5 LH:7 Gr III:1	CE:4 LH:6	CE:8 LH:2
Operation finding (hilar injury)	4 (80%)	8 (61.5%)	6 (60%)	1 (10%)
24-hr blood transfusion (mL)*	2600 \pm 1875	2000 \pm 1250	1950 \pm 875	1325 \pm 1700
<i>P</i> value		0.556		0.031

* Values are percentages or means \pm standard deviation. *P* value was determined by Mann-Whitney *U* test or Fisher's exact test. The significance was set at *P* < 0.05.

† CE, contrast extravasation; LH, large hemoperitoneum; Gr III, grade 3 injury based on American Association for the Surgery of Trauma Organ Injury Scale.

‡ Patients became unstable during CT scans.

§ Patients remained hemodynamically stable after CT scans.

¶ Patients became unstable while being observed.

|| Comparing to hemodynamically unstable patients in Group A.

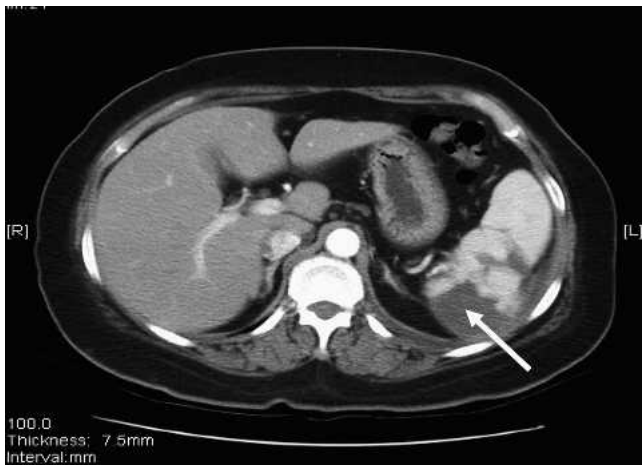

FIG. 2. Abdominal CT shows partial infarction of the spleen (arrow) at three months after angioembolization.

in four patients and large hemoperitoneum in six patients. In comparison, CT scans of 13 patients in Group B who became hemodynamically unstable during abdominal CT scans showed contrast extravasation in five patients and large hemoperitoneum in seven patients. The last patient had a grade III splenic injury. Ten patients in Group B who remained hemodynamically stable underwent SAE, and CT scans of these patients showed either contrast extravasation (8 patients) or large hemoperitoneum (2 patients). The procedure was successful and controlled the bleeding in eight patients including six with contrast extravasation and two with large hemoperitoneum. Seven of them had intrasplenic vessels embolized and the other patient had a main artery embolized for bleeding control. One patient began to bleed 12 hours after SAE. The other patient's bleeding was unable to be controlled due to technical difficulties. Follow-up images of these eight successfully embolized patients showed partial splenic infarctions at three months after the procedure (Fig. 2), but a complete resolution of the infarction by the sixth month.

Finally, the amount of blood transfusion during the first 24 hours and the duration from the presentation to the operating room of those patients who became unstable during CT scans were similar between the two groups ($P > 0.05$). However, among the 10 patients in Group A undergoing exploration within two hours of admission, all had splenectomy with the first 24-hour blood transfusion of 1950 ± 875 mL. In comparison, 10 patients underwent SAE only and received $1325 \pm 1,700$ mL of blood transfusion during the same period ($P < 0.05$).

Discussion

Many recent studies have examined factors that might influence the outcome of nonoperative manage-

ment and spleen salvage rate.^{10–14} Patients with splenic injury that are older than 55 years have not been recommended for nonoperative management because of decreased physiologic reserve, comorbidity, and reduced tolerance to trauma.¹⁵ However, others have found that older patients with splenic injury had similar risk for failure to that of younger patients.^{12, 13, 16} Our study did not find age to have any negative impacts on NOM success rates either before or after the adoption of SAE. Similarly, among patients with isolated splenic injury, we did not find ISS to be a negative predictor for NOM failure. In other words, additional injuries in the head, the chest, or the extremities did not have negative impact on the splenic salvage or NOM rates. However, our data need to be interpreted with caution, because we excluded patients with additional intra-abdominal organ injuries. Patients with higher ISS tend to have more severe associated abdominal injury (e.g., higher abbreviated abdominal injury scores) and are more likely to be unstable and require the prompt surgical intervention. These patients are likely to be excluded in the study. Taken together, our data suggest that among patients who are hemodynamically stable on presentation with isolated splenic injury, additional trauma to other body cavities should not deter the surgeon from managing the splenic injury nonoperatively.

In our study, the splenic hilar injury is an important predictor of NOM failure in hemodynamically stable patients. Even with the application of SAE, the bleeding of the hilum is difficult to control. This may be due to the abundant vasculature that increases the difficulty of the procedure. In comparison, contrast extravasation or pseudoaneurysm formation on CT scans can be controlled by SAE. As shown in Table 4, patients in SAE group had significantly less transfusion requirement during the first 24 hours. Ten patients in Group A became unstable while being closely observed after CT scanning. The emergency room to operating room time was significantly longer than those who went to the operating room from the ER (183 ± 61 min vs 112 ± 13 min, $P < 0.05$). CT scans of these patients showed signs suggesting NOM failure to be likely. SAE could have been done to avoid splenectomy in the majority of these patients. The first 24-hour blood transfusion was significantly more in Group A among patients who became unstable after admission and underwent splenectomy than those who underwent SAE ($P < 0.05$). We believe that SAE should be performed to control splenic bleeding especially in stable patients with factors to predict NOM failure.

Among 10 patients in Group B who underwent SAE, only eight patients (80%) had successfully controlled bleeding. The majority of them could be em-

bolized of the intrasplenic vessels. One patient had a tortuous splenic artery that made the SAE difficult and she became unstable during the procedure and was taken to the operating room for splenectomy. She had a near-hilar injury that was actively bleeding. The other failure occurred in a 71-year-old cirrhotic female patient who rebled 12 hours after the embolization of the main splenic artery and became unstable. A large and deep laceration of the splenic parenchyma into the hilum was found during the operation. Though liver cirrhosis is an unfavorable factor for NOM of blunt spleen injury,¹⁷ whether cirrhosis will affect the SAE success rate requires further investigation. One of the concerns about SAE is the splenic infarction.¹⁸ In this series, gelfoam was used as the embolizing agent. Partial parenchymal infarction was noted in all patients at three months either by ultrasound or CT examinations. It resolved by the end of six months. Five patients developed low-grade fever or mild pain after the procedure that resolved uneventfully. No other late complications (*e.g.*, abscesses or cysts) were found in these patients.

In conclusion, angioembolization seems to be an effective alternative to operative management of the splenic injury. By using criteria developed based on abdominal CT scans for angioembolization, we are able to improve splenic salvage rate and reduce blood transfusion requirement. However, future studies are needed to evaluate the role of SAE in hemodynamically unstable patients.

Acknowledgment

We thank Ms. Yu-Jun Chang for her assistance in data analysis.

REFERENCES

1. Nix JA, Costanza M, Daley BJ, et al. Outcome of the current management of splenic injuries. *J Trauma* 2001;50:835-42.
2. Peitzman AB, Heil B, Rivera L, et al. Blunt splenic injury in adults: Multi-institutional Study of the Eastern Association for the Surgery of Trauma. *J Trauma* 2000;49:177-89.
3. Velmahos GC, Toutouzas KG, Radin R, et al. Nonoperative treatment of blunt injury to solid abdominal organs: A prospective study. *Arch Surg* 2003;138:844-51.
4. Sclafani SJ, Shaftan GW, Scalea TM, et al. Nonoperative salvage of computed tomography-diagnosed splenic injuries: Utilization of angiography for triage and embolization for hemostasis. *J Trauma* 1995;39:818-27.
5. Haan JM, Bochicchio GV, Kramer N, et al. Nonoperative management of blunt splenic injury: A 5-year experience. *J Trauma* 2005;58:492-8.
6. Omert LA, Salyer D, Dunham M, et al. Implications of the "contrast blush" finding on computed tomographic scan of the spleen in trauma. *J Trauma* 2001;51:272-8.
7. Haan JM, Scott J, Boyd-Kranis RL, et al. Admission angiography for blunt splenic injury: Advantages and pitfalls. *J Trauma* 2001;51:1161-5.
8. Dent D, Alsbroom G, Erickson BA, et al. Blunt splenic injuries: High nonoperative management rate can be achieved with selective embolization. *J Trauma* 2004;56:1063-7.
9. Wahl WL, Ahrns KS, Chen S, et al. Blunt splenic injury: Operation versus angiographic embolization. *Surgery* 2004;136:891-9.
10. Schurr MJ, Fabian TC, Gavant M, et al. Management of blunt splenic trauma: Computed tomographic contrast blush predicts failure of nonoperative management. *J Trauma* 1995;39:507-13.
11. Moore EE, Shackford SR, Pachter HL, et al. Organ injury scaling: Spleen, liver and kidney. *J Trauma* 1989;29:1664-6.
12. Barone JE, Burns G, Svehlak SA, et al. Management of blunt splenic trauma in patients older than 55 years. *J Trauma* 1999;46:87-90.
13. Cocanour CS, Moore FA, Ware DN, et al. Age should not be a consideration for nonoperative management of blunt splenic injury. *J Trauma* 2000;48:606-10.
14. Ochsner MG. Factors of failure for nonoperative management of blunt liver and splenic injuries. *World J Surg* 2001;25:1393-6.
15. Godley CD, Warren RL, Sheridan RL, et al. Nonoperative management of blunt splenic injury in adults: Age over 55 years as a powerful indicator for failure. *J Am Coll Surg* 1996;183:133-9.
16. Myers JG, Dent DL, Stewart RM, et al. Blunt splenic injuries: Dedicated trauma surgeons can achieve a high rate of nonoperative success in patients of all ages. *J Trauma* 2000;48:801-6.
17. Fang JF, Chen RJ, Lin BC, et al. Liver cirrhosis: An unfavorable factor for nonoperative management of blunt splenic injury. *J Trauma* 2003;54:1131-6.
18. Ekeh AP, McCarthy MC, Woods RJ, et al. Complications arising from splenic embolization after blunt splenic trauma. *Am J Surg* 2005;189:335-9.